Case of Stargardt Disease Caused by Uniparental Isodisomy

Stargardt disease is the most common form of juvenile macular degeneration, with an incidence of 1 in 10 000 persons. Clinically, it is characterized by pisciform flecks at the level of the retinal pigment epithelium and a bull's-eye maculopathy.[1] A variant of Stargardt disease, fundus flavimaculatus, demonstrates a more peripheral distribution of flecks.[2] In 1997, mutations in the *ABCA4* gene on chromosome 1 were associated with both Stargardt disease and fundus flavimaculatus.[3] Stargardt disease is an autosomal recessive condition. Consequently, patients are expected to inherit 1 copy of a mutant *ABCA4* gene from each parent. However, we recently identified a patient affected with Stargardt disease who inherited 2 mutant alleles of the *ABCA4* gene from her father through a mechanism known as uniparental disomy.[4,5]

A female patient aged 15 years was diagnosed with Stargardt disease with visual acuities of 20/200 OD and 20/150 OS and characteristic retinal findings (**Figure 1**). Goldmann visual fields confirmed bilateral central scotomas, and a standard electroretinogram was normal. The patient was tested for *ABCA4* mutations using standard methods[6] and was found to be homozygous for an *ABCA4* mutation of proline to leucine at position 1380 (P1380L). Interestingly, only the patient's father is a carrier of the P1380L mutation. Her mother does not harbor this mutation (**Figure 2**). Maternity and paternity were confirmed by genotyping the family members with genetic markers including X and Y chromosome markers and 3 short tandem repeat polymorphisms located on chromosomes 4, 5, and 11. Quantitative polymerase chain reaction experiments confirmed that the patient was truly homozygous for P1380L (data not shown), suggesting that both copies of this mutation were paternally inherited due to uniparental disomy.

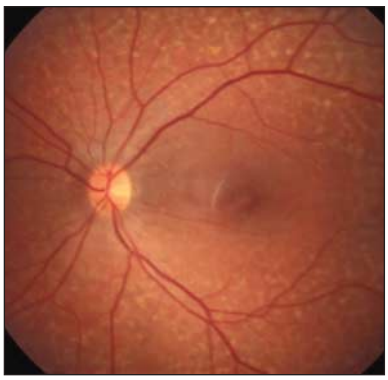

Figure 1. Fundus photograph of the patient's left eye shows macular and extramacular pisciform yellow flecks characteristic of Stargardt macular dystrophy.

An error in chromosome sorting (nondisjunction) may lead to offspring inheriting 2 copies of a chromosome from one parent and none from the other parent (uniparental disomy). In uniparental isodisomy, the offspring inherits a pair of identical chromosomes derived from only 1 of a parent's 2 homologous chromosomes. In uniparental heterodisomy, a portion of the inherited chromosomes is derived from both of a parent's homologous chromosomes and the other portion is derived from only 1 of the parent's chromosomes.

Nondisjunction during meiotic cell division leads to gametes with abnormal numbers of chromosomes (nullisomy or disomy). When these abnormal gametes form a zygote, either trisomy or monosomy occurs, which may lead to uniparental disomy by loss of the extra chromosome in early mitotic cell division (trisomy rescue) or by duplication of the monosomic chromosome (monosomy rescue). If a nullisomic gamete and a disomic gamete fortuitously combine to form a zygote, no such rescue is necessary to achieve the proper number of chromosomes (gamete complementation). Recessive alleles on the involved chromosome in uniparental disomy may become homozygous in offspring. Consequently, uniparental disomy may result in expression of a recessive disease inherited from only 1 parent. This non-Mendelian mechanism of disease inheritance has been observed in rod monochromacy,[7] retinitis pigmentosa,[8-11] and Leber congenital amaurosis.[10]

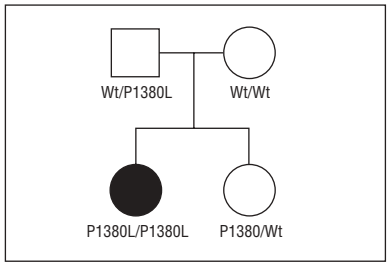

Figure 2. Family pedigree and genotypes at the *ABCA4* gene. The proband (filled symbol) has Stargardt disease and is homozygous for the P1380L mutation (mutation of proline to leucine at position 1380) in *ABCA4*. However, only 1 of her parents, her father, carries the mutation. Wt indicates wild type; square, male; and circle, female.

We investigated whether the patient inherited both P1380L alleles of the *ABCA4* gene from her father by genotyping the patient and her family at 24 short tandem repeat polymorphism genetic markers distributed across chromosome 1 using standard techniques[12] (**Figure 3**). For all of the 24 markers, the patient was homozygous for a marker allele possessed by her father, and 16 of these markers demonstrated nonmaternal inheritance of chromosome 1 alleles (neither marker allele was of maternal origin). The other 8 marker genotypes, although uninformative, were consistent with nonmaternal inheritance of chromosome 1. The patient's sister, however, exhibited normal Mendelian inheritance of chromosome 1 alleles from both parents. These data suggest that the patient is homozygous for the P1380L *ABCA4* mutation as a consequence of inheriting 2 identical copies of chromosome 1 from her father (uniparental paternal isodisomy).

The frequency of uniparental isodisomy in Stargardt disease was assessed by screening a panel of 830 unrelated patients for homozygosity at chromosome 1 markers. Forty of the 830 patients were homozygous at markers closely flanking *ABCA4*; however, none were homozygous across all of chromosome 1, ruling out the possibility of uniparental isodisomy (data not shown). Therefore, uniparental isodisomy occurs rarely in Stargardt disease at a frequency of less than 0.12% (1/831) of cases. Although unlikely, it remains possible that some of the 40 subjects in this experiment are homozygous for markers near the *ABCA4* gene as a consequence of uniparental heterodisomy.

Uniparental disomy of chromosome 1 has been inadvertently detected in studies of recessive disease.[9,13-18] Estimates of the prevalence

©2006 American Medical Association. All rights reserved.

Marker	Locus, cM	Patient		Mother		Father		Sister	
D1S468	4.22	2	2	1	2	2	2	1	2
*D1S1612**	16.22	2	2	1	3	2	2	1	2
*D1S1635**	23.35	2	2	1	3	2	3	1	3
D1S552	45.33	1	1	1	1	1	2	1	2
*D1S3721**	72.59	3	3	2	4	1	3	1	4
*D1S188**	126.16	2	2	3	4	1	2	2	4
*D1S2868**	126.16	1	1	2	3	1	2	1	3
*D1S2849**	126.16	2	2	1	3	2	3	1	2
*D1S406**	126.16	1	1	3	4	1	2	1	4
*D1S2779**	126.16	1	1	2	2	1	2	1	2
ABCA4 (P1380L)		L	L	P	P	P	L	P	L
D1S1587	128.73	2	2	1	2	2	2	2	2
Centromere		•	•	•	•	•	•	•	•
*D1S1671**	134.20	1	1	2	2	1	1	1	2
*D1S3723**	140.39	4	4	1	2	3	4	1	4
*D1S305**	159.32	1	1	2	2	1	2	1	2
*D1S1595**	161.05	1	1	2	3	1	1	1	3
D1S1699	170.84	1	1	1	1	1	2	1	1
D1S1677	175.62	2	2	2	3	2	1	2	3
*D1S2790**	190.98	4	4	1	2	3	4	1	4
*D1S1660**	212.44	1	1	2	3	1	1	1	3
D1S1726	214.08	2	2	2	3	1	2	1	2
D1S1632	214.08	1	1	1	3	1	2	2	3
124 F08	226.16	2	2	2	3	1	2	1	3
*D1S179**	252.12	3	3	1	2	3	3	2	3
*D1S1609**	274.53	2	2	1	3	2	3	1	3

Figure 3. Chromosome 1 genotyping of the patient and her family, who were all typed at 24 short tandem repeat polymorphism markers distributed across chromosome 1. For the patient and her sister, maternal chromosome 1 alleles are indicated with black shading, paternal alleles are indicated with gray shading, and alleles of indeterminate inheritance are unshaded. For each individual, alleles at each marker are shown arbitrarily in numerical order (parental haplotypes cannot be deduced from this small pedigree). For all of the 24 markers, the patient is homozygous for a marker allele possessed by her father. Sixteen of the 24 markers are informative (asterisks) and demonstrated nonmaternal inheritance. Two markers are completely uninformative in this pedigree and are not shown. This pattern of inheritance is consistent with uniparental paternal isodisomy. cM indicates centimorgan; L, leucine; and P, proline.

of uniparental disomy have been made by extrapolating data from such studies; however, these figures vary dramatically.[5] Currently, the prevalence of chromosome 1 uniparental disomy is unknown, but this phenomenon appears to be a relatively rare occurrence. These observations are consistent with our findings in which no additional cases of uniparental isodisomy were detected in a cohort of 830 patients with Stargardt disease.

To our knowledge, this is the first reported case of Stargardt disease caused by uniparental isodisomy. Although uncommon, this mode of inheritance should be considered in patients with Stargardt disease and an apparently homozygous mutation of the *ABCA4* gene.

John H. Fingert, MD, PhD
David A. Eliason, BA
Nicole C. Phillips, BA
Andrew J. Lotery, MD, FRCOphth
Val C. Sheffield, MD, PhD
Edwin M. Stone, MD, PhD

Correspondence: Dr Stone, Department of Ophthalmology, The University of Iowa College of Medicine, Iowa City, IA 52242 (edwin-stone@uiowa.edu).

Financial Disclosure: None.

1. Stargardt K. Über familiäre, progressive degeneration in der makulagegend des auges. *Albrecht Von Graefes Arch Ophthalmol*. 1909; 71:534-550.
2. Franceschetti A, Francois J. Fundus flavimaculatus [in French]. *Arch Ophtalmol Rev Gen Ophtalmol*. 1965;25:505-530.
3. Allikmets R, Singh N, Sun H, et al. A photoreceptor cell-specific ATP-binding transporter gene (ABCR) is mutated in recessive Stargardt macular dystrophy. *Nat Genet*. 1997;15:236-246.
4. Engel E. A new genetic concept: uniparental disomy and its potential effect, isodisomy. *Am J Med Genet*. 1980;6:137-143.
5. Engel E. Uniparental disomies in unselected populations. *Am J Hum Genet*. 1998;63:962-966.
6. Webster ARHE, Lotery AJ, Vandenburgh K, et al. An analysis of allelic variation in the ABCA4 gene. *Invest Ophthalmol Vis Sci*. 2001;42:1179-1189.
7. Pentao L, Lewis RA, Ledbetter DH, Patel PI, Lupski JR. Maternal uniparental isodisomy of chromosome 14: association with autosomal recessive rod monochromacy. *Am J Hum Genet*. 1992;50:690-699.
8. Gal A, Li Y, Thompson DA, et al. Mutations in MERTK, the human orthologue of the RCS rat retinal dystrophy gene, cause retinitis pigmentosa. *Nat Genet*. 2000;26:270-271.
9. Rivolta C, Berson EL, Dryja TP. Paternal uniparental heterodisomy with partial isodisomy of chromosome 1 in a patient with retinitis pigmentosa without hearing loss and a missense mutation in the Usher syndrome type II gene USH2A. *Arch Ophthalmol*. 2002;120:1566-1571.
10. Thompson DA, McHenry CL, Li Y, et al. Retinal dystrophy due to paternal isodisomy for chromosome 1 or chromosome 2, with homoallelism for mutations in RPE65 or MERTK, respectively. *Am J Hum Genet*. 2002;70:224-229.
11. Thompson DA, Gyurus P, Fleisher L, et al. Genetics and phenotypes of RPE65 mutations in inherited retinal degeneration. *Invest Ophthalmol Vis Sci*. 2000;41:4293-4299.
12. Heon E, Piguet B, Munier F, et al. Linkage of autosomal dominant radial drusen (malattia leventinese) to chromosome 2p16-21. *Arch Ophthalmol*. 1996;114:193-198.
13. Field LL, Tobias R, Robinson WP, Paisey R, Bain S. Maternal uniparental disomy of chromosome 1 with no apparent phenotypic effects. *Am J Hum Genet*. 1998;63:1216-1220.
14. Gelb BD, Willner JP, Dunn TM, et al. Paternal uniparental disomy for chromosome 1 revealed by molecular analysis of a patient with pycnodysostosis. *Am J Hum Genet*. 1998;62: 848-854.
15. Pulkkinen L, Bullrich F, Czarnecki P, Weiss L, Uitto J. Maternal uniparental disomy of chromosome 1 with reduction to homozygosity of the LAMB3 locus in a patient with Herlitz junctional epidermolysis bullosa. *Am J Hum Genet*. 1997;61:611-619.
16. Miura Y, Hiura M, Torigoe K, et al. Complete paternal uniparental isodisomy for chromosome 1 revealed by mutation analyses of the TRKA (NTRK1) gene encoding a receptor tyrosine kinase for nerve growth factor in a patient with congenital insensitivity to pain with anhidrosis. *Hum Genet*. 2000;107:205-209.
17. Takizawa Y, Pulkkinen L, Chao SC, et al. Mutation report: complete paternal uniparental isodisomy of chromosome 1: a novel mechanism for Herlitz junctional epidermolysis bullosa. *J Invest Dermatol*. 2000;115:307-311.
18. Dufourcq-Lagelouse R, Lambert N, Duval M, et al. Chediak-Higashi syndrome associated with maternal uniparental isodisomy of chromosome 1. *Eur J Hum Genet*. 1999;7:633-637.

©2006 American Medical Association. All rights reserved.